

Replication of HIV-1 in Dendritic Cell-Derived Syncytia at the Mucosal Surface of the Adenoid

Sarah S. Frankel,* Bruce M. Wenig,* Allen P. Burke,
Poonam Mannan, Lester D. R. Thompson,
Susan L. Abbondanzo, Ann M. Nelson, Melissa Pope,
Ralph M. Steinman†

Human immunodeficiency virus–type 1 (HIV-1) replicates actively in infected individuals, yet cells with intracellular depots of viral protein are observed only infrequently. Many cells expressing the HIV-1 Gag protein were detected at the surface of the nasopharyngeal tonsil or adenoid. This infected mucosal surface contained T cells and dendritic cells, two cell types that together support HIV-1 replication in culture. The infected cells were multinucleated syncytia and expressed the S100 and p55 dendritic cell markers. Eleven of the 13 specimens analyzed were from donors who did not have symptoms of acquired immunodeficiency syndrome (AIDS). The interaction of dendritic cells and T cells in mucosa may support HIV-1 replication, even in subclinical stages of infection.

HIV-1 undergoes active replication in infected individuals even during periods of clinical well-being (1, 2). It is important to identify sites of viral replication during the period of subclinical infection to understand pathogenesis and identify better therapies. Although lymph nodes are major reservoirs for extracellular virions, actively infected cells containing HIV-1 transcripts are infrequent and cells with intracellular viral protein are rare (3–9). Macrophages containing intracellular HIV-1 transcripts and Gag (p24) protein have been detected in the brains of infected individuals (10), but the specimens were from patients with terminal AIDS and the infected macrophages were present only in association with neurodegenerative changes that occur in some patients. The paucity of productively infected cells may mean that very few cells are responsible for viral replication in vivo or that active sites for HIV-1 replica-

tion have yet to be identified.

To investigate possible additional sites of virus replication, we examined specimens of adenoidal lymphoid tissue from 13 indi-

viduals, aged 20 to 42 years, two of whom were female. A detailed list of the patients is available on request. Each had undergone surgery between 1989 and 1995 to remove an enlarged adenoid, but the initial pathological analysis did not show changes associated with standard adenotonsillar infections or neoplasms. Further microscopic analysis at the Armed Forces Institute of Pathology revealed marked enlargement of the lymphoid follicles (B cell areas) and multinucleated giant cells. The latter are characteristic of chronic infections, but relevant organisms (tuberculous, fungal, parasitic, or viral) were not detected (11).

Within and just beneath the mucosa of the 13 specimens, cells were present that stained markedly for intracellular HIV-1 p24 antigen (12) (Fig. 1, B through E). The p24-positive cells either were large and irregularly shaped with a few nuclei or were “giant cells” with large numbers of nuclei and fewer dendrites. Weaker and diffuse staining for p24 was also observed in the underlying lymphoid follicles or germinal centers (Fig. 1B). The latter deposits likely represent extracellular antigen that was retained as antibody-coated virions on the surface of follicular dendritic cells (3, 6, 8, 13). Infected cells were not detected in the adenoids of two HIV-1–negative controls (Fig. 1A). In situ hybridization with radio-

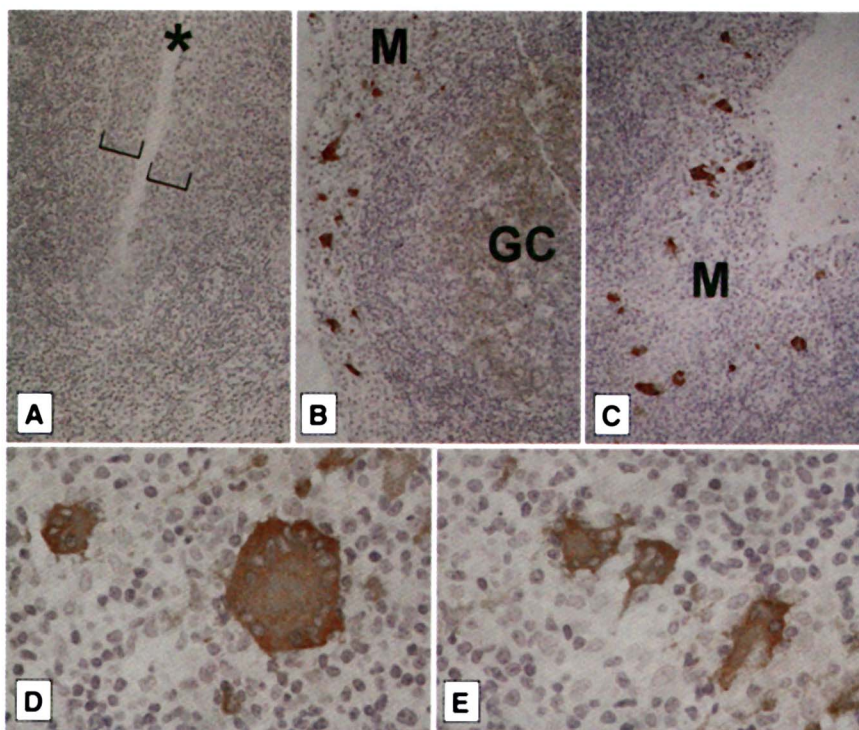


Fig. 1. Immunostaining of adenoidal lymphoid tissue for HIV-1 p24 protein. (A) Positive cells were not detected in the adenoid of uninfected individuals. Brackets indicate the mucosal epithelium that lines invaginations or plications of the surface (*). (B through E) Infected cells (brown) were present in and just beneath the mucosa (M) of all the HIV-1–positive specimens studied. Weak p24 staining in the germinal centers (GC) of the underlying lymphoid tissue is apparent in (B). HIV-1–infected syncytia, or multinucleated giant cells, are evident at higher magnification in (D) and (E).

S. S. Frankel and A. M. Nelson, AIDS Division, Department of Infectious and Parasitic Disease Pathology, Armed Forces Institute of Pathology, Washington, DC 20306–6000, USA.

B. M. Wenig and L. D. R. Thompson, Department of Otolaryngic and Endocrine Pathology, Armed Forces Institute of Pathology, Washington, DC 20306–6000, USA.

A. P. Burke and P. Mannan, Department of Cardiovascular Pathology, Armed Forces Institute of Pathology, Washington, DC 20306–6000, USA.

S. L. Abbondanzo, Department of Hematologic and Lymphatic Pathology, Armed Forces Institute of Pathology, Washington, DC 20306–6000, USA.

M. Pope and R. M. Steinman, Laboratory of Cellular Physiology and Immunology, Rockefeller University, New York, NY 10021, USA.

*These authors contributed equally to this research.

†To whom correspondence should be addressed.

labeled antisense, but not sense, probes (Lofstrand) confirmed the presence of many infected cells, including giant cells, within and beneath the adenoid mucosa. However, in situ hybridization was not required to detect infected cells because the p24 stain was marked and discrete.

With the exception of one individual who refused HIV-1 testing, all of the patients exhibited serum antibodies to HIV-1. However, only 2 of 13 patients had experienced symptoms of AIDS, most denied high-risk behavior, and 11 were unaware that they were infected. Therefore, this active replication of HIV-1 was occurring in otherwise asymptomatic individuals.

The infected dendritic cells (DCs) and syncytia in the adenoid resembled cells that are derived from skin and support HIV-1 replication in culture (14). Like skin, the nasopharyngeal epithelium was stained with antibodies to keratin (15) (Fig. 2, A and B). Many DCs were also identified with antibodies to the S100 protein (16) (Fig. 2C). The infected cells were located within and just beneath this keratinized surface (Fig. 2, A and B). Unlike skin, the mucosal

surface of the adenoid possesses two distinct features: (i) The surface forms many shallow plications (Fig. 2C), which enhance the accessibility of the lymphoid organ to stimuli from the pharynx (17), and (ii) the mucosa contains not only DCs but also many T and B lymphocytes (17, 18).

We determined the phenotype of the giant cells within and beneath the mucosa, all of which were strongly positive for p24 antigen (Fig. 1, D and E). The giant cells stained strongly for S100 (Fig. 3A), which is present in DCs but not other types of white blood cells (16). The giant cells also stained moderately for the p55 actin-bundling protein (Fig. 3B) that is present in mature or activated DCs but not other types of white blood cells (19). Numerous irregularly shaped p55-positive cells were apparent in the vicinity of the syncytia (Fig. 3B), which we assume to be mature DCs. The staining of adenoid giant cells with antibodies to S100 and to p24 was specific for HIV-1-infected mucosa; neither type of antibody stained macrophage giant cells from HIV-1-negative leprosy patients or the lung macrophages from HIV-1-positive tu-

berculosis patients (20).

Our observations reveal three new features of HIV-1 infection in situ:

1) Many heavily infected cells are evident in individuals who are clinically well. Most of the organs we examined were from asymptomatic individuals, and all had cells that were strongly positive for intracellular viral protein.

2) The cells in which HIV-1 actively replicates in situ express markers of DCs (S100 and p55). Productively infected DCs in the epidermis, which is homologous to the nasopharyngeal epithelium, have rarely been observed in previous studies (21). We confirmed the absence of intracellular p24 labeling in 12 lymph nodes and 12 skin specimens from other HIV-1-infected individuals (20). However, skin differs from adenoid mucosa in that T cells are rare within the epithelium, and most of the DCs are immature in phenotype and function. That is, the DCs lack high concentrations of major histocompatibility complex class II and accessory molecules, marked T cell stimulatory function, and the p55 actin-bundling protein. When DCs are allowed to emigrate from cultured explants of human skin, the cells acquire markers of mature, immunostimulatory cells (22), including p55, and form conjugates with CD4⁺ T cells (14, 22). When in contact in vitro, the T cells and activated DCs efficiently support HIV-1 replication (14). By extension, we propose that the adenoid mucosa promotes the interaction of T cells with DCs that are activated repeatedly by persistent environmental stimuli in the nasopharynx.

3) Viral replication occurs predominantly in syncytia in infected nasopharyngeal tissue. Syncytium formation, as judged by the behavior of HIV-1 on addition to certain cell lines, is a feature of only some viral isolates and is regarded as a late sequela of HIV-1 infection (23). We do not have access to the virus from this group of patients, all of whom are residents of the United States without a significant travel history, so we are unable to determine if the viruses with which they are infected would be classified as syncytium inducing or non-syncytium inducing with standard cell lines. However, syncytia were a standard feature of infection within the mucosa of the adenoid even in asymptomatic disease. Syncytia reproducibly develop in vitro when HIV-1 is added to mixtures of DCs and T cells, even with virus that is non-syncytium inducing with cell lines. The syncytia express both DC and T cell markers and are the main sites in which p24 antigen and budding virions are present (14). We have not succeeded in identifying the CD3 T cell marker in mucosal syncytia, although many CD3⁺ T cells were in contact with or near the syncytia, as visualized with rabbit polyclonal antibodies

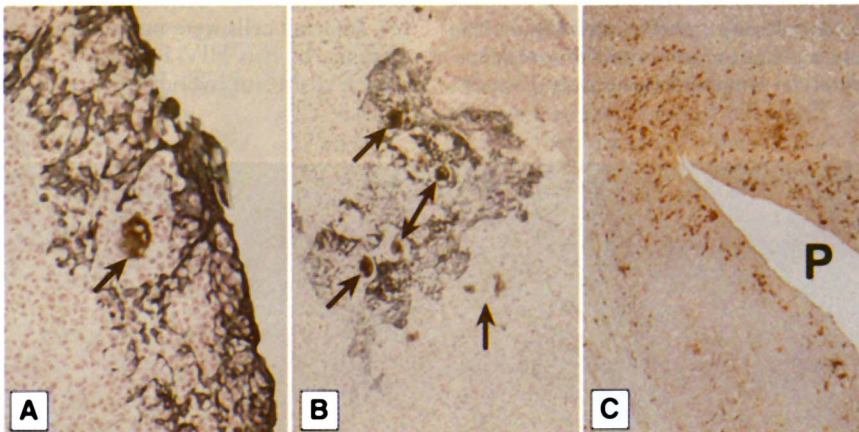
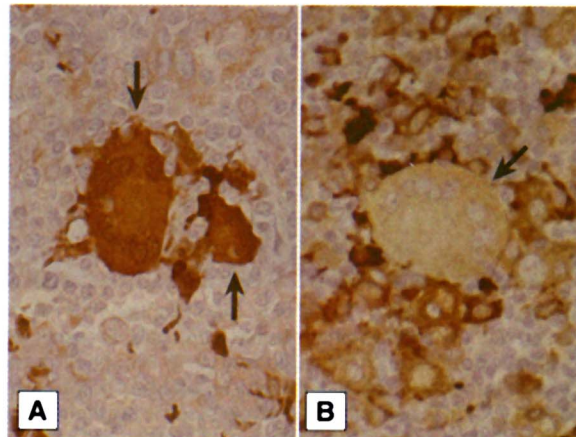


Fig. 2. Immunostaining of adenoid tissue with antibodies to keratin (A and B) or to S100 (C). (A and B) The HIV p24-positive profiles (arrows) are present within and beneath the epithelium of the adenoid, which is stained blue with antibodies to keratin. (C) The adenoid epithelium contains many S100-positive DCs (brown), especially at the depths of the plications (P).

Fig. 3. Immunostaining of the DC antigens S100 (A) and p55 (B) in HIV-1-infected giant cells (arrows).



to CD3 (20). The T cell marker may be down-regulated after fusion with DCs, or the DCs may simply require contact with T cells to support viral replication.

Efforts can now be directed to determine whether DCs within the many lymphoid organs of the pharynx, collectively termed Waldeyer's ring, consistently represent a major site for HIV-1 replication early in disease. Infants who swallow virus from mothers during birth or breast feeding also may be infected initially in these tissues. Other extralymphoid sites in which DCs and T cells may interact and promote HIV-1 replication include inflamed genital surfaces and the afferent lymphatics that originate from just beneath the mucosa. Simian immunodeficiency virus DNA has been detected in presumptive DCs just beneath the uterine mucosa of monkeys that were acutely infected with the virus intravaginally (24). Further attention to tissues that contain interacting DCs and T cells may provide insight into critical sites for HIV-1 replication in situ.

REFERENCES AND NOTES

1. D. D. Ho *et al.*, *Nature* **373**, 123 (1995).
2. X. Wei *et al.*, *ibid.*, p. 117.
3. K. Tenner Racz *et al.*, *Am. J. Pathol.* **123**, 9 (1986).
4. P. Biberfeld *et al.*, *ibid.* **125**, 436 (1986).
5. K. Tenner Racz *et al.*, *AIDS* **2**, 299 (1988).
6. P. U. Cameron, R. L. Dawkins, J. A. Armstrong, E. Bonifacio, *Clin. Exp. Immunol.* **68**, 465 (1987).
7. H. J. Schuurman, W. J. Krone, R. Broekhuizen, J. Goudsmit, *Am. J. Pathol.* **133**, 516 (1988).
8. C. H. Fox *et al.*, *J. Infect. Dis.* **164**, 1051 (1991).
9. J. Embretson *et al.*, *Nature* **362**, 359 (1993).
10. B. Weiser *et al.*, *Proc. Natl. Acad. Sci. U.S.A.* **87**, 3997 (1990).
11. The specimens were negative for microorganism stains (Brown-Hopps tissue Gram stain, periodic acid-Schiff stain, Grocott's methenamine silver stain, Ziehl-Neelsen acid-fast stain) and for immunolabeling with antibodies to Epstein-Barr virus, herpes simplex virus, or cytomegalovirus.
12. Formalin-fixed, paraffin-embedded tissues were sectioned, stained with the Kal-1 monoclonal antibody to HIV-1 p24 (DAKO) followed by peroxidase-avidin-biotin complex, and counterstained with hematoxylin.
13. K. Tenner Racz, P. Racz, M. Dietrich, P. Kern, *Lancet* **i**, 105 (1985); J. A. Armstrong and R. Home, *ibid.* **ii**, 370 (1984); G. Pantaleo *et al.*, *Nature* **362**, 355 (1993).
14. M. Pope *et al.*, *Cell* **78**, 389 (1994); M. Pope, S. Gezelter, N. Gallo, L. Hoffman, R. M. Steinman, *J. Exp. Med.* **182**, 2045 (1995).
15. Keratin was identified with two specific monoclonal antibodies followed by alkaline phosphatase-conjugated secondary antibodies (DAKO). Antigens reactive with a monoclonal antibody to p24 and rabbit polyclonal antibodies to S100 (DAKO) were detected with a peroxidase reaction product.
16. K. Takahashi *et al.*, *Am. J. Pathol.* **116**, 497 (1984); H. J. Kahn, A. Marks, H. Thom, R. Baumal, *Am. J. Clin. Pathol.* **79**, 341 (1983).
17. J. Klein, *Immunology* (Blackwell, Boston, 1990), p. 52; D. W. Fawcett, *A Textbook of Histology* (Saunders, Philadelphia, 1986).
18. L. P. Ruco *et al.*, *J. Pathol.* **176**, 391 (1995).
19. G. Mosialos *et al.*, *Am. J. Pathol.* **148**, 593 (1996).
20. S. S. Frankel *et al.*, unpublished data.
21. D. C. Kalter *et al.*, *J. Immunol.* **146**, 3396 (1991); J. Kanitakis *et al.*, *AIDS Res. Hum. Retroviruses* **5**, 293 (1989); H. Muller *et al.*, *Res. Virol.* **144**, 59 (1993); A. Gianetti *et al.*, *J. AIDS* **6**, 329 (1993).
22. M. Pope, M. G. H. Betjes, H. Hirmand, L. Hoffman, R. M. Steinman, *J. Invest. Dermatol.* **104**, 11 (1995).
23. S. Jurriaans *et al.*, *Virology* **204**, 223 (1994).
24. A. I. Spira *et al.*, *J. Exp. Med.* **183**, 215 (1996).
25. Supported by NIH grant AI24775, the Dorothy Schiff Foundation, the Norman and Rosita Winston Fellowship Program (M.P.), the Direct Effect AIDS Researcher Program, Army research and development contract 90MM0604, and an American Registry of Pathology research grant. We thank R. Virmani for encouragement. The opinions and assertions contained herein are the private views of the authors and are not to be construed as official or as reflecting the views of the Departments of the Navy, Army, or Defense.

1 November 1995; accepted 1 February 1996